

Analytical Study of Anatomical Variations of Nose And Pns in Ct Scan And Chronic Sinusitis

Dr.D.Dakshina Murthy¹, Dr. B. Rama Chandra Rao², Dr.S.Surya Prakasa Rao³.

¹dr.D.Dakshina Murthy, Assistant Professor, Andhra Medical College,

²dr. B. Rama Chandra Rao, Assistant Professor, Andhra Medical College,

³dr.S.Surya Prakasa Rao, Professor, Andhra Medical College.

Abstract:

Back Ground: Sinusitis affects millions of people each year and is a major cause of concern worldwide. Chronic rhino-sinusitis is an inflammation of Nose and Paranasal sinuses and the aetiology of it is multifactorial. Anatomical variations of nose and paranasal sinuses are one of the most important aetiological factor for chronic sinusitis. The approach to patients with chronic rhinosinusitis is endoscopic surgery which aims at removing the obstruction of the main drainage pathway. The Osteomeatal complex based essentially on the concept that obstruction perpetuates the sinus disease. This in turn requires the surgeon to have detailed knowledge of the anatomy of the lateral Nasal wall, Paranasal sinuses and surrounding vital structures and of the large number of anatomical variants in the region. CT Scan of Para Nasal Sinuses has become mandatory for all patients undergoing Functional Endoscopic Sinus Surgery. It depicts the anatomical complexities of Osteomeatal complex in a simpler way and acts as a road map for endoscopic sinus surgery.

Aim: the Aim of the study was to

1. Detect prevalence of anatomical variations of Nose and PNS in Chronic Rhino - Sinusitis in Computed Tomography.

2. Study the association of anatomical variations of Nose and PNS in Chronic Rhino-Sinusitis.

Materials And Methods: Descriptive cross sectional studies in which 144 consecutive cases of chronic rhino-sinusitis patients attending ENT Out –patient department, who had chronic sinusitis for more than 3 months duration not responding to the medical line of treatment and who were willing to undergo functional endoscopic sinus surgery satisfying the inclusion criteria were studied. The results were expressed in percentage and proportions. The retrospective study was conducted in patients at the Government ENT Hospital, Andhra Medical College, Visakhapatnam, who had presented between October 2012 – September 2015.

Results: In our study it was observed that 1 or more types of anatomical variants were observed in 112 cases out of 144 cases. The most frequent being the Deviated Nasal Septum (73.2%) and the choncha bullosa (45.5%), and the other less common anatomical variants observed were paradoxical middle turbinate, Aggar Nasi cells, Haller cell, Onodi cell and Septal Cell.

Conclusion: Prevalence of multiple anatomical variations are more in our study in comparision to single anatomical variation. Deviated Nasal Septum was the most common anatomical variation encountered in our study followed by Choncha Bullosa.

Keywords: Anatomical Variations, Chronic Rhinosinusitis, CT scan, ParaNasal Sinuses, Osteo-meatal complex.

I. Introduction

Chronic Rhino sinusitis is chronic inflammation of Nose and Para Nasal Sinuses. Its patho-physiology seems to be multi -factorial. The approach to patients with chronic rhino-sinusitis has changed after Messerklinger published the first comprehensive account of technique of nasal endoscopy and its application to the diagnosis and treatment of sinonasal diseases (2). The endoscopic surgery aims at removing the obstruction of the main drainage pathway in the osteomeatal complex. It is based essentially on the concept that such obstruction perpetuates the sinus disease. The key underlying concept behind minimally invasive functional endoscopic sinus surgery is the osteomeatal complex (OMC) – the small compartment located in the region between the middle turbinate and the lateral nasal wall in the middle meatus – represents the region for drainage of anterior ethmoid, maxillary and frontal sinuses. Obstruction of OMC causes a vicious cycle of events that lead to sinusitis. Its obstruction leads to mucosal congestion that decreases air flow and leads to further obstruction (5).

Surgical clearance of these chronically infected sinuses while maintaining their ventilation and drainage is the treatment of choice (6). To achieve this goal, there should be some diagnostic modalities which guide us towards exact diagnosis and safe intervention. Over the past few decades, both CT and nasal endoscopy have been used successfully as diagnostic modalities in sinus disease. The purpose of these investigations is to

determine the mucosal abnormalities and bony anatomic variations of paranasal sinus and assess the possible pathogenicity of these findings in patients undergoing evaluation for sinusitis.

The revolutionary changes in the surgical treatment of rhino sinusitis in recent years, particularly in endoscopic surgery, require the surgeons to have detailed knowledge of the anatomy of the lateral nasal wall, paranasal sinuses and surrounding vital structures and of the large number of anatomical variants in the region, many of which are detectable only by the use of CT (7). Presumably these variations might induce osteomeatal obstruction, preventing mucus drainage and predisposing to chronic rhino sinusitis. Identifying predisposing factors for chronic sinusitis are therefore very important. The frequency of the anatomic variations may differ among the different ethnic groups. The aim of the study was to report the frequency of these variations in patients with chronic rhino sinusitis who have attended the Outpatient department, Government ENT Hospital, Andhra Medical College, Visakhapatnam.

II. Patients And Methods

Retrospective Review of CT scan PNS was done at the government ENT Hospital, Andhra Medical College, Visakhapatnam and comprised the data of 144 patients who had visited the hospital from October 2013 – September 2015. CT scan was done for all patients who had Chronic Rhino-sinusitis. The patients had CT scan PNS 5 mm Coronal, Sagittal and axial sections done, they were analyzed for anatomical variations which were as follows.

CT scan detection of anatomical variations: Deviated Nasal Septum (DNS) was the most common variation in 82 patients, followed by Concha bullosa in 51 patients. Other variations found were Uncinate Deviation/ Hypertrophy, Aggar Nasi Cell, Paradoxical Middle turbinate, Haller cell, Onodi Cell and Pneumatization of vomerine bone (Tab-1).

Tab - 1

Anatomical Variation	Frequency	Percentage (%)
DNS	82	73.2%
Chonchabullosa	51	45.5%
Uncinate Deviation/Hypertrophy	18	16.1%
Paradoxical Middle Turbinate	14	12.5%
Aggar Nasi Cells	9	8%
Onodi Cells	6	5.3%
Haller cells	3	2.7%
Pneumatization of Vomerine Bone	3	2.7%

III. Discussion

The Surgical Management of CRS has evolved over the years. External facial incisions, extensive nasal packing and prolonged hospital stays have been replaced by minimally invasive surgery. This involves opening the obstructed ostia to provide normal ventilation with preservation of adjacent mucosa. While excellent results have been reported in the literature to date, given the close relation of the paranasal sinuses to important structures such as the orbit and skull base, if complications occur in surgery, they are usually dangerous and harmful.

Anatomical variations in the sinonasal region are common. Recent advances in CT Scanning and the widespread of ESS, as well as the presence of universal agreement in the variation nomenclature and terminology has made the extent of these variations apparent. Local anatomic variations including concha bullosa, deviated nasal septum (DNS), Haller cells, paradoxical middle turbinates, agger nasi cells and many others may be the source of middle meatal obstruction and subsequent rhinosinusitis.

In our study we found anatomical variation in osteomeatal complex of 77.7 % chronic rhino sinusitis patients, out of which 49.4% had two or more anatomical variations and the remaining 28.3% had single anatomical variation. Similar findings were reported by Liu X et al., who observed prevalence of about 81% anatomical variations in chronic rhinosinusitis cases. Severino Aires de Araujo Neto et al., reported relatively less anatomical variations 65% in the osteomeatal complex of the chronic rhino sinusitis cases. Perez et al., also observed similar prevalence of anatomical variations in the chronic sinusitis cases.

Nasal Septum Deviaton:

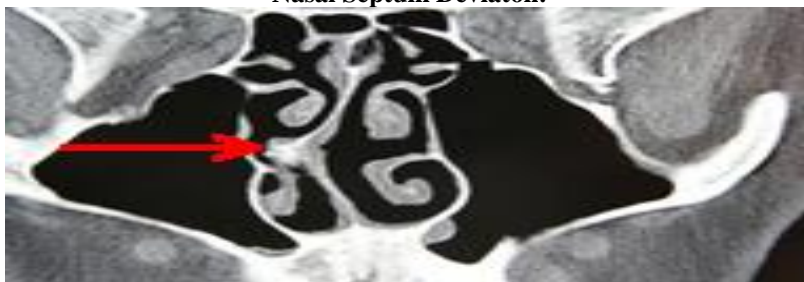

Fig - 1

Nasal septum is fundamental in the development of the nose and paranasal sinuses. It is the epiphyseal platform for the development of the facial skeleton. 73.2% of the patients in our study presented with nasal septal deviation (Table/Fig-1). Deviated nasal septum causes a decrease in the critical area of the osteomeatal unit predisposing to obstruction and related complications. Similar finding were observed by Perez et al., who reported the prevalence of deviated nasal septum to be about 80%. In fact in various studies the finding of nasal septal deviation ranged from 14.1% to 80%, Dutra and Marchiore et al., 14.1% Arslan et al., 36% Earwaker et al., 44%. Dua et al., and Asruddin et al., found prevalence of 44% and 38% of deviate nasal septum in their respective studies. Stallmann et al., and Mamtha et al., also reported lesser prevalence of 60 % and 65% deviated nasal septum in chronic rhino sinusitis cases respectively.

Concha Bullosa

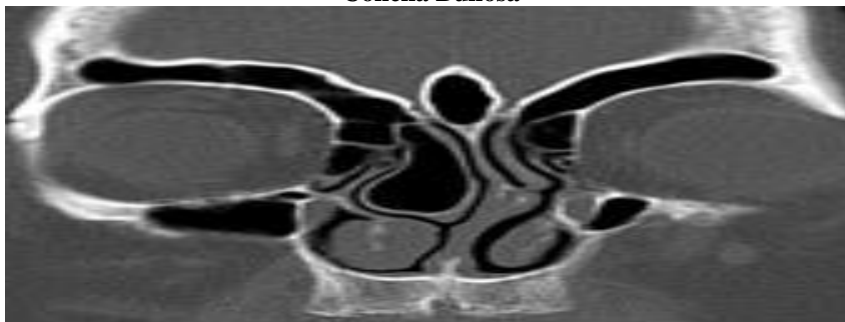

Fig - 2

Concha bullosa (pneumatized middle turbinate) (Fig – 2) has been implicated as a possible aetiological factor in the causation of recurrent chronic sinusitis. It is due to its negative influence on paranasal sinus ventilation and mucociliary clearance in the middle meatus region as quoted by Tonai(22). Concha bullosa was seen in 45.5% of the chronic rhinosinusitis cases which is almost similar to as reported by Bolger et al., and Yousem et al., respectively. Perez-Pinas et al., Scribano et al., reported higher prevalence of concha bullosa i.e.73% and 67% in chronic rhino sinusitis cases. The prevalence of concha bullosa in our study is on the higher side when compared to the findings of Stallmann et al.,(20), Maru et al.,(25). Wani et al., Dua et al., Asruddin et al., Mamatha et al., Zinreich et al., Llyod et al., and Weinberger et al reported further less prevalence of about 36%, 30%, 28%, 16%, 15% 14% and 15% respectively(1,6,19,21,27,29).

Paradoxically Curved Middle Turbinate

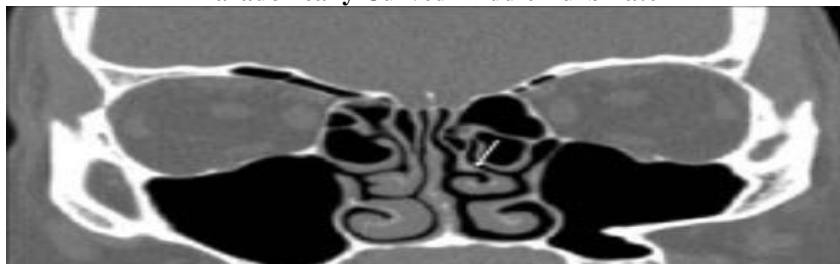


Fig - 3

The Middle turbinate may be paradoxically curved i.e., bent in the reverse direction. This may lead to impingement of the middle meatus and thus to sinusitis. Stammberger and Wolf (30) accepted paradoxical curvature of the middle turbinate as an etiological factor for CRS because it may cause obliteration or alteration

in nasal air flow dynamics. It was found in 12.5% of the patients; the prevalence is similar to that of 12% by Asruddin et al.,(19) and 15% Llyod(28).

Uncinate Process of Ethmoid Bone: We observed that the uncinate process may be deviated or pneumatized. Uncinate deviation can impair sinus ventilation especially in the anterior ethmoid, frontal recess and infundibulum regions. The deviated uncinate was found in 10.7% of cases which is similar to the findings of the study by Maru et al.,(25) but higher than that reported by Bolger et al., (7) 2.5%, Dua et al.,(6) 6%.

Hypertrophied uncinate process causes narrowing of the hiatus semilunaris and the ethmoid infundibulum. It has also been suggested as a predisposing factor for impaired ventilation of the anterior group of sinuses and frontal sinus. Hypertrophy of the uncinate process was observed in 5.6% of the cases which is very less as compared to the findings of Wani et al., who reported it to be 21% in chronic rhino sinusitis cases(1).

Aggar Nasi Cell

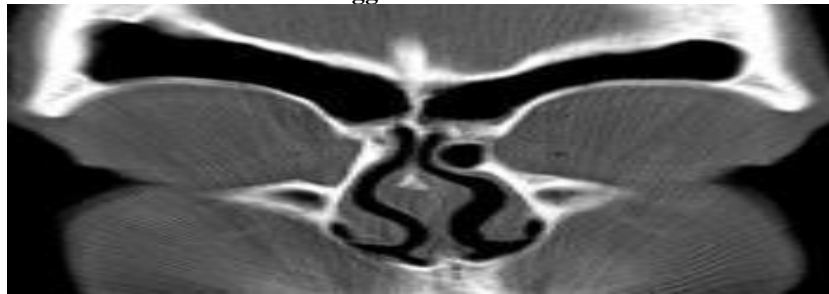

Fig - 4

Aggar nasi cells (Fig – 4) lie just anterior to the anterosuperior attachment of the middle turbinate and frontal recess. These can invade the lacrimal bone or the ascending process of maxilla. These cells were observed in 8% of patients in our study. Similar results were observed by Liu X et al., (12) and Llyod et al., (28) who reported the prevalence of aggar nasi cells as 7.8% and 8.5% in chronic rhinosinusitis cases whereas in the study by Dua et al., (6) agger nasi cells were found to be present in 9 patients(8%). The prevalence is very less as compared to 98.5% by Bolger (7), 88.5% by Maru(25), 86.7% by Tonai and Baba (32) and 48% by Asruddin(19).

Haller's Cell

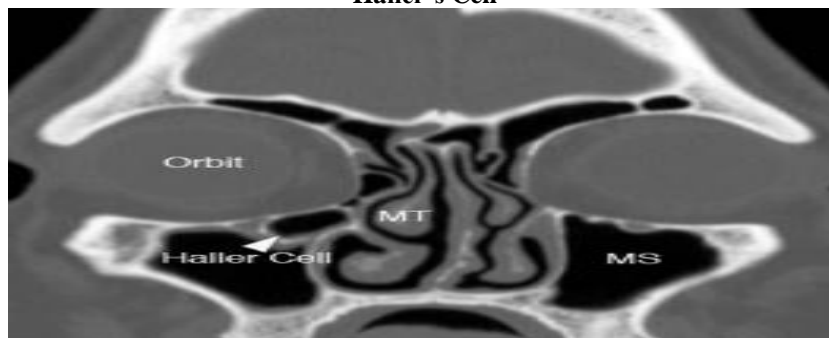

Fig-5

Zinreich et al., (33) and Kennedy et al., (34) described Haller's cells (Fig – 5) as ethmoid air cells found inferior to the ethmoid bulla adhering to the roof of the maxillary sinus, in continuity with the proximal infundibulum, which formed part of the lateral wall of the infundibulum. They are considered as ethmoid cells that grow into the floor of orbit and may narrow the adjacent ostium of the maxillary sinus especially if they become infected (35). Davis et al., (36) noted the haller cell is thought to cause chronic sinusitis cases by impinging on the ostium of the maxillary sinus and infundibulum by inhibiting the ciliary function, leading to obstruction of the ostium.

The prevalence of Haller's cells in our study was 2.7%. Similar findings were observed by Liu X et al., (12) who reported the prevalence of about 1 % of Haller cells in 297 chronic rhino sinusitis cases in a study conducted in Sun Yat Sen University of Medical Sciences. This is again very less as compared to that reported by Kayalioglu et al., (37) 5.5%, Dua et al., (6) 16%, Llyod et al., (35) 15%, Perez-Pinas et al., (14) 20%, Tonai

and Baba (32) 36%, Bolger et al., (7) 45.9%, Maru et al.,(25) 36%, Alkire BC et al., (26) 39.9% and Asruddin et al., (19) 28% respectively.

Onodi Cell: Onodi cell is the most posterior ethmoid air cell that extends laterally. This extension is near the carotid canal and close to the optic nerve, which emphasizes the clinical importance of considering this anatomic variation prior to any attempt for invasive intervention. The surgeon must pay close attention to the occasional Onodi cell in pre-operative evaluation to avoid potential complications of ESS. Onodi cell was found in 6(5.3%) patients in the current study. Other studies have reported Onodi cell presence from 0% to 9%. (38, 39).

IV. Conclusion

In our study it was concluded that the Anatomical variations are common in the osteomeatal complex. Prevalence of multiple anatomical variations was more common in our study in comparison to single anatomical variation. Deviated nasal septum was the most common anatomical variation encountered in our study followed by concha bullosa and paradoxically bent middle turbinate.

Computed Tomography of the paranasal sinuses has improved the visualization of paranasal sinus anatomy and has allowed greater accuracy in evaluating paranasal sinus disease. It evaluates the osteomeatal complex anatomy which is not possible with plain radiographs. Anatomical variations studied on CT scan are found to block the OMC and cause chronic sinusitis. The blockade in the OMC leads to impaired drainage of maxillary, frontal and anterior ethmoid thus causing chronic sinusitis. Thus, this study has re-emphasized the concept that Osteomeatal complex is the key factor in the causation of chronic sinusitis. Removal of disease in Osteomeatal complex region is the basic principle of FESS which is best appreciated on CT scan.

References

- [1]. Wani AA, Kanotra S, Lateef M, Ahmad R, Qazi SM, Ahmad S. CT scan evaluation of the osteomeatal complex. *Indian J Otolangol Head Neck Surg.* 2009;61:163-68.
- [2]. Messerklinger W. *Endoscopy of the nose.* Baltimore, MD: Urban & Schwarzenberg; 1978.
- [3]. Stammberger HR and Kennedy DW. Paranasal sinuses: anatomic terminology and nomenclature. The anatomic terminology group. *Ann Otol Rhinol Laryngol Suppl.* 1995;167:7-16.
- [4]. Freitas Ap; Boasquesvisque EM. Anatomical variations of the osteomeatal complex: tomographic findings in 200 patients. *Radiol. Bras. J.* 2008; 41:149-54.
- [5]. Becker Samuel S, Becker Daniel G. *Diagnosis and Management of Disorders of the Nose and Sinuses.* Available from: URL: http://www.sinustreatmentcenter.com/BOOK/chapter11_0109.pdf. Accessed July 15, 2011.
- [6]. Dua K, Chopra H, Khurans As and Munjal M. CT scan variations in chronic sinusitis. *Ind J Radio Imag.* 2005;15:315-20.
- [7]. Bolger WE, Butzin CA, Parsons DS. Paranasal sinus bony anatomic variations and mucosal abnormalities: CT analysis for endoscopic sinus surgery. *Laryngoscope.* 1991;101:56-64.
- [8]. Schaefer SD, Manning S, Close LG. Endoscopic paranasal sinus surgery: indications and considerations. *Laryngoscope.* 1989;99:1-5.
- [9]. Kennedy DW, Senior BA. Endoscopic sinus surgery: a review. *Otolaryngol Clin North Am.* 1997;30:313-30.
- [10]. Salnab M, Matai V, Salam MA. The impact of functional endoscopic sinus surgery on health status. *Rhinology.* 2004;42:98-102.
- [11]. Damm M, Quante G, Jungehulsing M, Stennert E. Impact of functional endoscopic sinus surgery on symptoms and quality of life in chronic rhinosinusitis. *Laryngoscope.* 2002;112:310-15.
- [12]. Liu X, Zhan G, Xu G. Anatomic variations of osteomeatal complex and correlation with chronic sinusitis: CT evaluation. *Zhonghua Er Bi Yan Hou Ke Za Zhi.* 1999;34:143-46.
- [13]. Severino Aires de Araujo Neto, Paulo de Sa Leite Martins, Antonio Soares Souza, Emlio Carlos Elias Baracat, Livio Nanni. The role of osteomeatal complex anatomical variants in chronic rhinosinusitis. *Radiol Bras.* 2004;39:227-32.
- [14]. Perez-Pinas, Sabate J, Carmona A, Catalina-Herrera CJ, Jimenez-Castellanos J. Anatomical variations in the human paranasal sinus region studied by CT. *J Anat.* 2000;197:221-27.
- [15]. Takanishi R. The formation of the nasal septum and the etiology of the septal deformity. *Acta Otolaryngol.* 1987;443:1-154.
- [16]. Dutra DL, Marchiori E. Helical CT of the paranasal sinuses in children: evaluation of inflammatory sinus disease. *Radiol Bras.* 2002;35:161-69.
- [17]. Arslan G. Concha bullosa and nasal septum deviation. *Am J Neuroradiol.* 2005;26:1882.
- [18]. Lusk RP, McAlstar B, Fouley A. Anatomic variations in pediatric chronic sinusitis. *Otolaryngol Clin North Am.* 1996;29:75-91.
- [19]. Asruddin, Yadav SPS, Yadav RK, Singh J. Low dose CT in chronic sinusitis. *Indian J Otolaryngol.* 1999-2000;52:17-22.
- [20]. Stallman JS, Lobo JN, Som PM. The incidence of concha bullosa and its relationship to nasal septal deviation and paranasal sinus disease. *Am J Neuroradiol.* 2004; 25:1613-18.
- [21]. Mamtha H, Shamasundar NM, Bharathi MB, Prasanna LC. Variations of osteomeatal complex and its applied anatomy: a CT scan study. *Indian J Sci Technol.* 2010;3:904-07.
- [22]. Danese M, Duvosin B, Agrifoglio A, Cherpillod J, Krayenbuhl M. Influence of naso-sinusal anatomic variants on recurrent, persistent or chronic sinusitis: X-ray computed tomographic evaluation in 112 patients. *J Radiol.* 1997;78:651-57.
- [23]. Yousem DM. Imaging of the sinonasal inflammatory disease. *Radiology.* 1993;188:303-14.
- [24]. Scribano E, Ascenti G, Casio F, Racchiusa S, Salamone I. Computerized tomography in the evaluation of anatomic variations of the osteomeatal complex. *Radio Med (Torino).* 1993;86:195-99.
- [25]. Maru YK, Gupta Y. Concha bullosa: frequency and appearances on sinonasal CT. *Indian J Otolaryngol.* 1999-2000;52:40-45.
- [26]. Alkire BC, Bhattacharyya N. An assessment of sinonasal anatomic variants potentially associated with recurrent acute rhinosinusitis. *Laryngoscope.* 2010;12:631-34.
- [27]. Zinreich SJ, Albayram S, Benson ML, Oliverio PJ. The osteomeatal complex and functional endoscopic surgery. In: *Head and neck surgery.* Som PM and Curtin HD (eds) Mosby Inc, St Louis. pp:149-73.

- [28]. Llyod GA. CT scan of the paranasal sinuses:study of a control series in relation to endoscopic sinus surgery. *Laryngo Rhino Otol*.1990;104:477-81.
- [29]. Weinberger DG, Anand VK, AL-Rawi M, Cheng HI, Messina AV.Surgical anatomy and variations of the onodi cell. *AM J Rhinol*.1996;10:365-70.
- [30]. Stammberger H, Wolf G. Headaches and sinus disease: the endoscopic approach. *Ann Oto Rhinol Laryn*.1988;97:3-23.
- [31]. Al-Qudah MA. Anatomical variations in sino-nasal region: A computer tomographic (CT) study. *J Med J*.2010;44:209-97.
- [32]. Tonai A, Baba S.Anatomic variations of the bone in sinonasal CT.*Acta Otolaryngol Suppl*.1996;525:9-13.
- [33]. Zinreich SJ, Kennedy DW, Rosenbaum AE, Gayler BW, Kumar AJ, Stammberger H.Paranasal sinuses: CT imaging requirement for endoscopic surgery. *Radiology*.1987;163:769-75.
- [34]. Zinreich SJ, Kennedy DW, Gayler BW.Computer tomography of nasal cavity and paranasal sinuses:An evaluation of anatomy for endoscopic sinus surgery. *Clear images*. 1988;1:2-10.
- [35]. Llyod GA , Lund VJ, Scadding GK. CT of the paranasal sinuses and functional endoscopic surgery: a critical analysis of 100 symptomatic patients. *Laryngol Otol*. 1991;105:181-85.
- [36]. Davis WE, Templer J Parsons DS. Anatomy of the paranasal sinuses. *Otolaryngol. Clin.North Am*.1996;29:57-91.
- [37]. Kayalioglu G, Oyar O, Govsa F. Nasal Cavity and paranasal sinus bony variations: a computed tomographic study. *Rhinology*.2000;38:108-13.
- [38]. Talaiepour AR, Sazgar AA, Bagheri A. Anatomic variations of the paranasal sinuses on CT scan images. *J Dentistr Tehran Univ Med Sci* 2005;2(4).
- [39]. Mazza D, Bontempi E, Guerrisi A, Del Monte S, Cipolla G, Perrone A, et al. Paranasal sinuses anatomic variants:64-slice CT evaluation. *Minerva Stomatol* 2007;56:311-8.